

## Reliability of Panoramic-Radiograph to Determine the Position of Third-Molar from Inferior-Alveolar-Canal

(Kebolehpercayaan Radiograf-Panorama untuk Menentukan Posisi Molar Ketiga dari Kanal Inferior Alveolus)

AZIZAH AHMAD FAUZI\*, MOHAMED EBRAHIM PARKER, EJ NORVAL & PHRABHAKARAN NAMBIAR

### ABSTRACT

*Cone-beam-computed-tomography (CBCT) has been useful in providing insights of relevant anatomy prior to surgical procedures, including the assessment of the proximity of impacted mandibular-third-molar to the inferior-alveolar-canal (IAC). It is important to understand the reliability of conventional panoramic-radiograph in the assessment of this criterion since it is more commonly used as first line radiographic approach due to its availability and lower radiation dose. This study aimed to investigate the reliability of conventional panoramic-radiograph in the evaluation of the proximity of impacted mandibular-third-molar root tip to the IAC by correlating the results with CBCT. A total of 65 root tips of impacted mandibular-third-molars that had both panoramic radiographs and CBCT images were included in this retrospective study. Two trained observers participated in all image evaluations. A prepared standard 1 cm ruler was used to measure the proximity of the third-molar root apices to the IACs. Measurements recorded in this study were categorized into positive (root apex above a roof of IAC), zero (root apex was superimposed on IAC) and negative (root apex below a roof of IAC). Data analysis was carried out using student t-test. In this study, both observers recorded statistically significant differences in the measurement between third-molars root apices and the IAC from panoramic radiographs and CBCT images. The low reliability of panoramic radiograph to assess the vertical proximity between these two anatomical structures suggests the importance of additional assessment with CBCT in cases where panoramic radiograph shows superimposition of the third molar root on the roof of the canal and presence of root below the roof of the IAC.*

*Keywords: Panoramic radiography; third molar*

### ABSTRAK

*Sinaran-kon-tomografi-berkomputer (CBCT) amat berguna dalam memberikan kefahaman berkenaan anatomi berkaitan sebelum prosedur pembedahan, termasuklah penilaian terhadap kedudukan mandibular-molar-ketiga-terimpak ke kanal inferior alveolus (IAC). Adalah penting untuk memahami kebolehpercayaan radiograf-panorama konvensional dalam penilaian kriteria ini memandangkan ia sering digunakan sebagai pendekatan radiografi baris hadapan kerana lebih mudah diperolehi dan mempunyai dos radiasi yang rendah. Kajian ini bertujuan untuk mengenal pasti kebolehpercayaan radiograf-panorama konvensional dalam penilaian kedudukan mandibular-molar-ketiga-terimpak ke IAC dengan mengaitkan keputusannya dengan CBCT. Sebanyak 65 hujung akar mandibular-molar-ketiga-terimpak yang mempunyai kedua-dua radiograf-panorama dan imej CBCT dipilih dalam kajian retrospektif ini. Dua pemerhati terlatih terlibat dalam penilaian keseluruhan imej. Pembaris berpiawai 1 cm disediakan bagi mengukur proksimiti akar molar ke IAC. Ukuran yang direkod dalam kajian ini dikategorikan kepada ukuran yang bernilai positif (akar apeks di atas bumbung IAC), sifar (akar apeks bertindih dengan IAC) dan negatif (akar apeks di bawah bumbung IAC). Analisis data dilakukan dengan menggunakan ujian-t pelajar. Dalam kajian ini, kedua-dua pemerhati merekodkan perbezaan statistik yang signifikan dalam ukuran antara apeks akar molar-ketiga dan IAC daripada radiograf-panorama serta imej CBCT. Kebolehpercayaan yang rendah bagi radiograf-panorama untuk menilai proksimiti menegak antara kedua-dua struktur anatomi ini mencadangkan kepentingan penilaian tambahan dengan CBCT dalam kes radiograf-panorama yang menunjukkan pertindihan akar pada bumbung molar-ketiga dan kehadiran akar di bawah bumbung IAC.*

*Kata kunci: Molar ketiga; radiograf-panorama*

### INTRODUCTION

Knowing the exact position of the mandibular-third-molar root apex to the IAC will help the surgeon to determine the risk of inferior-alveolar-nerve injury following surgical removal of mandibular-third-molar. This is important prior to obtain informed consent from the patient and decide the most appropriate treatment plan.

There are several radiographic approaches which have been used for preoperative assessment of the relationship between the roots of mandibular-third-molar to the IAC (Ghaeminia et al. 2009). Panoramic radiography has been used as a common diagnostic modality in dentistry, including the assessment of the impacted mandibular-third-molar. Despite being an inexpensive radiography

procedure, this imaging modality suffers from image magnification, superimposition, ghost images and distortion (Hassan 2010).

In the presence of CBCT scanners which have been developed specifically for dental and maxillofacial imaging (Scarfe & Farman 2008), this technology is becoming more commonly used in dentistry. The geometric and small size of the isotropic voxels of the CBCT volumetric data sets which range from 0.076 to 0.4 mm provides high pixel resolution with CBCT images (Scarfe & Farman 2008).

The absence of both magnification and distortion in secondary reconstructed images from CBCT volumetric data has also been described, hence, measurements performed on this reconstruction slice can be assumed to have a one: one relationship with the actual object (Snyder 2007). Unlike panoramic radiography which uses an average dental arch as focal trough, the ability of the CBCT technology to customize the focal trough shape to suit an individual dental arch allows for improved visualization of the anatomical structures of the region of interest. It is generally agreed that CBCT proved to be a reliable technique for visualizing anatomical structures in the maxillofacial region including the IAC, and for assessing its relationship to the adjacent roots of teeth (Angelopoulos et al. 2008; Sawamura et al. 2003; Tantanapornkul et al. 2007). However, the higher radiation dose and cost of CBCT in comparison to panoramic radiography limits the use of this modality to cases where conventional radiographic findings justify further assessment with CBCT (SEDEXCT project 2011). Understanding the reliability of panoramic-radiograph in the assessment of third-molar to the IAC will provide better insight about the need of CBCT assessment prior to removal of impacted mandibular-third-molar.

The aim of this study was to investigate the reliability of conventional panoramic-radiograph in the evaluation of the proximity of impacted mandibular-third-molar root tip to the IAC by correlating the results obtained by means of CBCT.

## MATERIALS AND METHODS

### SAMPLE COLLECTION

A sample size of 65 root tips of impacted mandibular-third-molars that had both panoramic radiographs and CBCT images were included in this retrospective study. Approval

from the research ethics committee, University of Western Cape and medical ethics committee, University of Malaya were obtained prior to commencement of the study.

Initially, CBCT images were selected from existing records of patients who went for CBCT assessment prior to surgical removal of the third-molar. Then, the matching conventional panoramic images were searched from a patient records database for subsequent comparison with the CBCT images. Panoramic and CBCT machines with their operating kVp and mA that were used for radiographic acquisition in this study were described in Table 1.

The inclusion criteria employed in this study were patients older than 18 years old, the presence of fully visible impacted mandibular third molars and visible IACs. Any radiographic record which showed incomplete root formation, pathology or resorption in apical area of mandibular third molars was excluded in this study.

### SAMPLE PREPARATION AND DATA COLLECTION

All the images were viewed by two trained observers in Maxillofacial Radiology. The procedures for image preparation and assessment were summarized in Figure 1.

### STATISTICAL ANALYSIS

All measurements from both observers were collected and entered into a spread sheet. Means and standard deviation of the measurements recorded by both observers were calculated for each imaging modality. The reliability of panoramic radiographs in the assessment of the proximity of the root apex to the IAC was evaluated statistically by comparing panoramic radiographs measurements with CBCT image measurements using the student t-test. The student t-test was also used to evaluate the inter-observer agreement in this study.

## RESULTS

In the assessment of the vertical position of 65 mandibular third molar root apices from the roof of IACs (Table 2), 44 of the cases showed negative measurement from the panoramic radiography image evaluation. This finding also showed that most of the impacted mandibular third molars showed intrusion of the root into the IAC when panoramic radiographs were assessed. The lengths of these roots within the IACs were measured to be between 0.15

TABLE 1. A list of machines used for image acquisition in this study

Name of machines	kVp	mA	Type of radiograph produced	Magnification factor
Veraview	60 to 70 kVp	5 to 10 mA	Digital panoramic radiograph	1.3
PC-1000	80 to 90 kVp	6 mA	Film based (analogue) panoramic radiograph	1.23
i-CAT	120 kVp	8 mA	CBCT images	none
NewTom VGi	110 kVp	15 mA	CBCT images	none

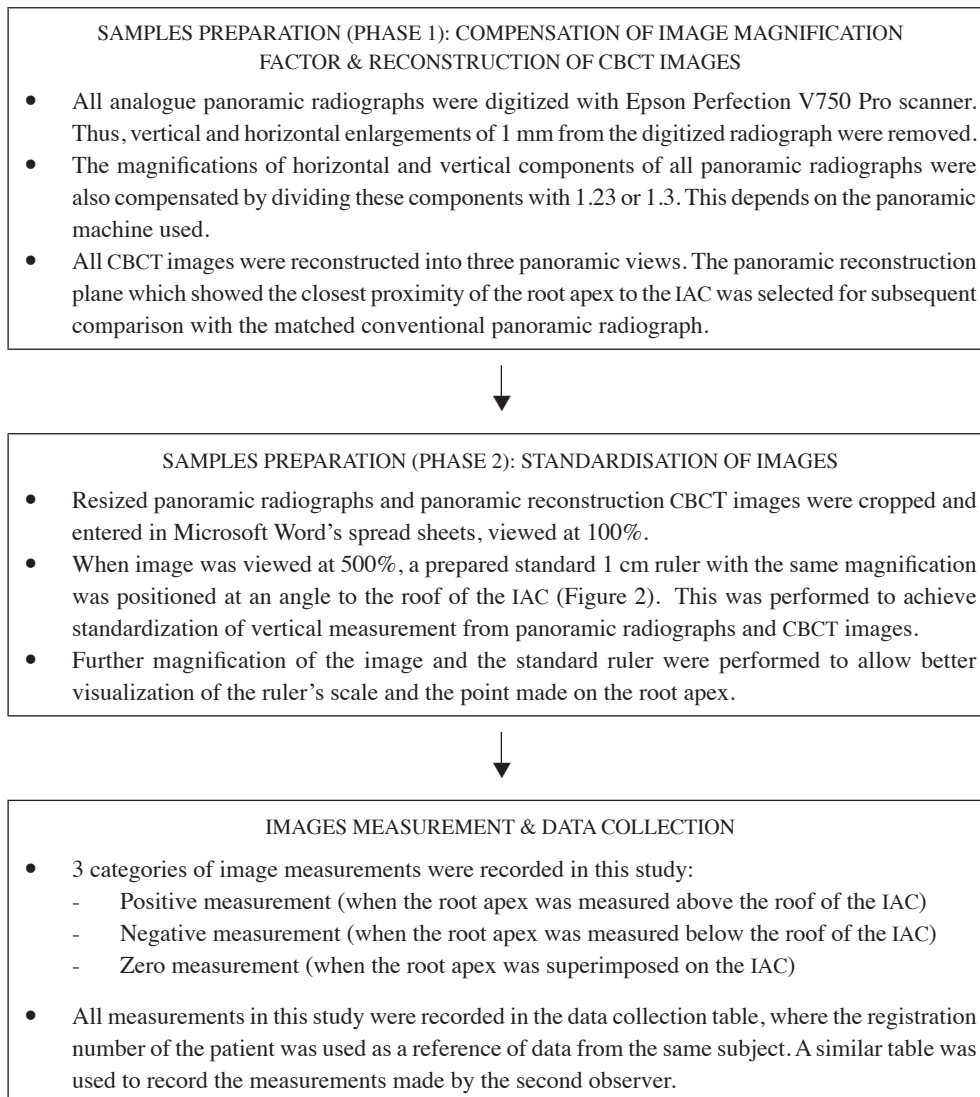


FIGURE 1. A flow chart to describe the procedures which were followed for preparation of samples (panoramic radiographs and CBCT images) as well as its assessment




FIGURE 2. The standardize position of the magnified 1 cm ruler which is placed at an angle to the roof of the canal

TABLE 2. A table of data which presents the vertical position of 65 mandibular-third-molar root apices in relation to the roof of IACs, from panoramic radiographs and CBCT images. *M* and *m* represent mean (SD) of maximum and minimum values measured in mm, respectively

Evaluation categories	Panoramic radiograph			CBCT images		
	No. of roots	<i>m</i>	<i>M</i>	No. of roots	<i>m</i>	<i>M</i>
Root apices below the roof of alveolar canal (-ve measurement)	44	0.15±0.071	5.6±0.141	33	0.05±0.071	4.2±0.000
Root apices above the roof of alveolar canal (+ve measurement)	17	0.2±0.000	2.75±0.071	27	0.1±0.014	4.75±0.071
Root apices superimposed on the roof of alveolar canal (zero measurement)	4	-	-	5	-	-

and 5.6 mm. On CBCT, only 33 root apices were found within the alveolar canal, and the lengths ranged between 0.05 and 4.2 mm.

On the other hand, the numbers of root apices located above the IACs which gave positive measurements in panoramic radiographs as well as CBCT images were 17 and 27 root apices, respectively. On panoramic radiographs, the thickness of bone height separating the root apices from the roof of the canal ranged from 0.2 to 2.75 mm. Meanwhile, on CBCT images the height ranged from 0.1 to 4.75 mm. Several superimpositions of the root apices on the roof of IACs had also been found in both imaging modalities and these were recorded as zero measurement. There were four root apices found to be superimposed on the roof of inferior alveolar canals from panoramic radiographs and five root tips on CBCT images.

An additional finding in this study indicated that eleven out of forty four roots were located within the canal from panoramic radiographs but were actually located superior to the canal on CBCT panoramic reconstruction slices. Two out of seventeen roots which were located less than 1 mm above the IAC in panoramic radiographs showed root protrusion into the canal in the CBCT images. In these two cases, we also found that the impacted molars were also associated with other special panoramic features. These additional radiographic features include interruption of lamina dura at the apex of third molar and narrowing of IAC. On both cases, CBCT images showed interruption of IAC's cortical roof with 0.1 - 0.5 mm of third molar root apices within the canal.

From this study, both observers showed significant difference between CBCT images and panoramic radiographs when measuring the vertical position between the root apices to the roof of the canals. The mean difference between panoramic radiographs and CBCT images when measuring the vertical distance between impacted mandibular third molar root apices and the roof of the IACs, recorded by the first observer was 0.580 mm ( $p < 0.001$ ). The difference was statistically significant between the two methods. The mean difference between CBCT images and

panoramic radiographs measurements made by the second observer was 0.529 mm ( $p < 0.001$ ), which also indicated a significant difference between both methods. This finding was demonstrated in the plot of CBCT image measurements against panoramic radiograph measurements (Figure 3). It could be seen from this plot that the red points representing CBCT image measurements were widely dispersed around the trend line of panoramic radiograph measurements, thus, indicating real bias between both methods.

In addition to this, the mean differences between the observer's measurements for both methods were also evaluated to determine the presence of bias. Using the paired version of the t-test, the mean difference in panoramic radiograph measurements between the first and the second observers was 0.047 mm, which was small but turned out to be significantly different from zero ( $p = 0.020$ ). At this stage, one might assume that the inter-observers agreement in the measurement of panoramic radiographs was low. However, by plotting panoramic measurements made by the first observer on the X-axis and panoramic measurements by the second observer on the Y-axis, the points clustered closely around the straight line reflecting the presence of only small bias between the observers' measurements on panoramic radiographs (Figure 4). The significant difference in the paired version of the test was explained by comparing the numbers of negative and positive differences in these two sets of panoramic radiograph measurements. From the assessment, the proportion of the negative difference was 0.3. This value was significantly different from 0.5; thus contributing to the significant difference in the paired version of the t-test, although a good inter-observers agreement was demonstrated from the plot of panoramic measurements by the first observer versus panoramic measurements by the second observer.

The mean difference in the measurements of CBCT images between the two observers was 0.0031 mm and was not significantly different from zero ( $p = 0.837$ ). This showed the absence of bias in the CBCT measurements made by both observers. A good inter-observers agreement

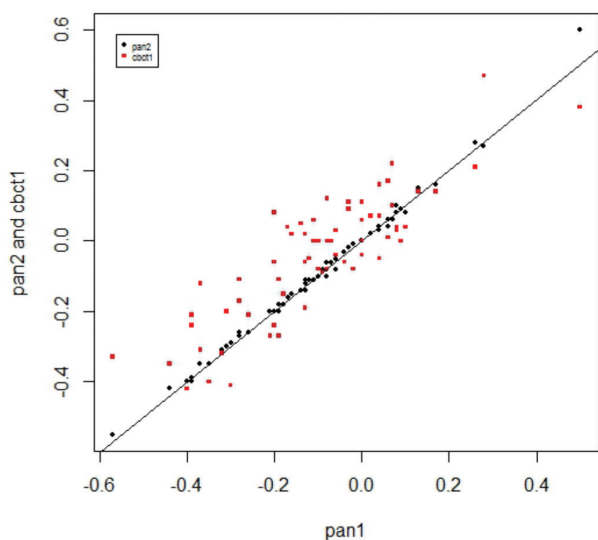


FIGURE 3. A plot of X and Y axes employed to compare CBCT image measurements by 1st observer (cbct1) versus the panoramic radiograph measurements counterpart (pan1)

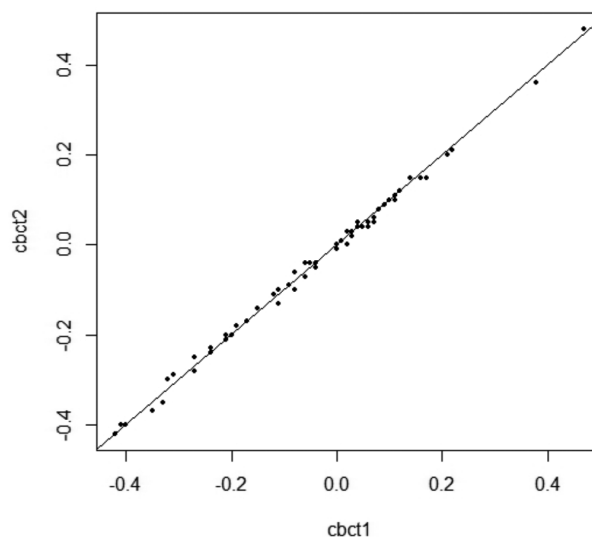


FIGURE 5. A plot of X and Y axes employed to compare measurements of CBCT images by 1st observer (cbct1) versus 2nd observer (cbct2)

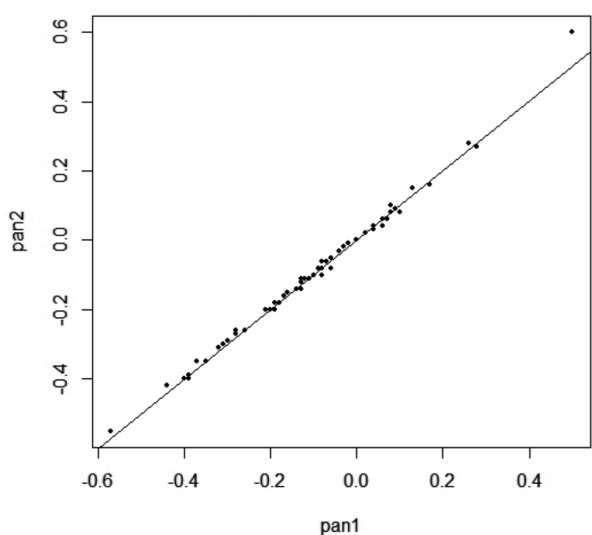


FIGURE 4. A plot of X and Y axes employed to compare measurements on panoramic radiographs by 1st observer (pan1) versus 2nd observer (pan2)

in CBCT measurements was also demonstrated in Figure 5, which showed a close relationship of the clustering of points around the straight line.

#### DISCUSSION

Understanding the limitation of conventional radiograph in the assessment of impacted third molar is paramount in determining the need of CBCT in selected cases and avoids unnecessary radiation exposure to the patient. Several studies have been made to compare the diagnostic accuracy of panoramic radiograph with CBCT and their findings are recorded as in Table 3.

From the literature reviews which are listed in Table 3, it can be concluded that five out of seven studies (71.4%) suggest panoramic radiograph is less accurate than CBCT. Quantitatively, we found that CBCT proved more accurate by  $\pm 0.53$  to  $0.58$  mm than panoramic radiograph in the measurement of the vertical position of mandibular third molar root apices to the IAC. This result is statistically significant between the two imaging modalities.

In a study of the proximity of maxillary third molars to the maxillary sinus by Hassan (2010), it had been described that superimposition of anatomical structures on conventional radiographs may result in over-projected root in the sinus. In the same manner, superimposition of buccal and lingual roots in conventional radiographs may also lead to over projection of mandibular tooth roots into the IAC.

In panoramic radiography, vertical magnification associated with this imaging modality is small and fairly constant. However, objects that are oblique which present with both vertical and horizontal components can appear slightly curved because of the significant change in the magnification of the horizontal component (Geist 2001). Since most molar roots are oblique, image distortion of this anatomical structure is likely to be present on panoramic radiographs.

In this study, although the magnification factors of panoramic radiographs were compensated before any measurements were made, the influence of the magnification factor may not be totally eliminated as the vertical and horizontal magnifications on conventional panoramic images performed by a single panoramic machine vary from one another at different rates, even when the object is placed within the focal trough. Thus, superimposition of the anatomical structures, image distortion and magnification remain the main factors which

TABLE 3. A list of literature review which compare the diagnostic accuracy of CBCT and panoramic radiographs in the assessment of impacted mandibular third molar with IAC

	Research findings
Neugebauer et al. 2008	Diagnostic findings from CBCT and panoramic radiography in the assessment of the vertical position of the root tip of mandibular third molars to the IAC (superior, inferior or at level of the canal), presented with similar data
Ghamenia et al. 2009	Panoramic image is comparable to CBCT image in predicting neurovascular bundle exposure, despite its limitation to assess the horizontal relationship of the mandibular third molar root apex to the IAC
Gomes et al. 2008	Panoramic radiograph does not has a high diagnostic accuracy when it is used in the assessment of risk in surgical extractions of lower third molars
Tantanapornkul et al. 2007 Ghaeminia et al. 2011	The diagnostic accuracy of CBCT was superior to panoramic radiography in predicting neurovascular bundle exposure following assessment of the relationship of the third molar root tip to the IAC
Hasegawa et al. 2013	Panoramic findings mostly inconsistent (62.5%) to CBCT findings. Thus, in planning surgical removal of mandibular third molar, panoramic radiography alone does not provide sufficiently reliable images to assess the risk associated with nerve exposure
Peker et al. 2014	Less accuracy in panoramic radiograph may indicate further preoperative assessment of impacted mandibular third molar with CBCT especially when darkening of the roots and interruption of the white line are observed on panoramic images

are responsible for the inaccurate measurements of the conventional panoramic images found in the present study. The low reliability of panoramic radiographs to determine the vertical distance between the third molar root apices and the canal as demonstrated in this study suggest the importance of employing CBCT as additional diagnostic modality for better evaluation of the impacted tooth.

In this study, we also found that two out of seventeen roots which were located above the IAC on panoramic radiographs showed protrusion into the canal from the CBCT images. Whereas, eleven out of forty four roots which were located within the canal on panoramic radiographs were actually located superior to the roof of the IAC on CBCT images.

In relation to the findings, it can be concluded that eleven of forty four cases (25%) with a high risk of nerve injury on panoramic radiographs showed alteration from the high risk to low risk after CBCT panoramic reconstruction slices were analyzed. On the other hand, two of seventeen cases (11.8%) with a lower risk of nerve injury where the root apices were located above the canals changed into high risk, as CBCT images demonstrated root protrusion into the canal. In consistent to the study by Susarla and Dodson (2007), we found that, additional pre-operative evaluation of impacted mandibular third molar with CBCT can be significant in terms of determination of the risk associated with inferior alveolar nerve injury following extraction of the tooth.

As described by Hasegawa et al. (2013) and Neves et al. (2012), this study recommends additional assessment of impacted mandibular third molar with CBCT when

panoramic radiographs suggest the presence of a root in the IAC or superimposition of the root on the canal.

Presences of these panoramic features are more commonly associated with the risk of IAC exposure in impacted mandibular third molar cases. In such cases, further evaluation with CBCT may be necessary to determine the most appropriate treatment plan such as coronectomy or extraction of the third molar. It is also important for clinician to inform the patient about the possibility of IAC exposure even though panoramic radiograph shows the root is located above the IAC. As demonstrated in this study, the presence of root above the IAC in panoramic radiograph may also associated with IAC exposure, although the risk is low. This may occur particularly in cases where there is less than 1 mm bone height between mandibular third molar and IAC, narrowing of canal or interruption of lamina dura at the third molar root apex.

#### CONCLUSION

The presence of protrusion of mandibular third molar roots in the IAC on panoramic radiographs does not always signify association of the root apices to the neurovascular bundle within the canal. In a similar fashion, the absence of root protrusion in the IAC on panoramic radiograph does not necessary indicate dissociation of the root apices from the canal on CBCT images.

The reliability of panoramic radiograph to assess the vertical proximity of the mandibular root apex to the IAC is low. It is recommended in this study to use CBCT as secondary diagnostic modality when panoramic radiograph

shows superimposition of the third molar root on the roof of IAC and the presence of root below the roof of the canal. Additional evaluation with CBCT in such cases is important to determine the actual risk associated with the inferior alveolar nerve injury following surgical removal of impacted mandibular third molar.

## REFERENCES

- Angelopoulos, C., Thomas, S.L., Hechler, S., Parissis, N. & Hlavacek, M. 2008. Comparison between digital panoramic radiography and cone-beam computed tomography for the identification of the mandibular canal as part of presurgical dental implant assessment. *J. Oral Maxillofac. Surg.* 66(10): 2130-2135.
- Geist, J.R. 2001. *Panoramic Radiography. Sullivan-Schein Dental 04AS1601*. <http://www.Henryschein.com/us-en/images/Dental/CEHP/Panoramic.pdf>. Accessed on 24th January 2013.
- Ghaemina, H., Meijer, G.J., Soehardi, A., Borstlap, W.A., Mulder, J., Vlijmen, O.J., Bergé, S.J. & Maal, T.J. 2011. The use of cone beam CT for the removal of wisdom teeth changes the surgical approach compared with panoramic radiography: A pilot study. *Int. J. Oral Maxillofac. Surg.* 40(8): 834-839.
- Ghaemina, H., Meijer, G.J., Soehardi, A., Borstlap, W.A., Mulder, J. & Bergé, S.J. 2009. Position of the impacted mandibular third molar in relation to the mandibular canal. Diagnostic accuracy of cone beam computed tomography compared with panoramic radiography. *Int. J. Oral Maxillofac. Surg.* 38(9): 964-971.
- Gomes, A.C., Vasconcelos, B.G.E., Silva, E.D., Caldas Ade, F. Jr. & Pita Neto, I.C. 2008. Sensitivity and specificity of pantomography to predict inferior alveolar nerve damage during extraction of impacted lower third molars. *J. Oral Maxillofac. Surg.* 66(2): 256-259.
- Hasegawa, T., Ri, S., Shigeta, T., Akashi, M., Imai, Y., Kakei, Y., Shibuya, Y. & Komori, T. 2013. Risk factors associated with inferior alveolar nerve injury after extraction of the mandibular third molar-a comparative study of preoperative images by panoramic radiography and computed tomography. *Int. J. Oral Maxillofac. Surg.* 42(7): 843-851.
- Hassan, B.A. 2010. Reliability of periapical radiographs and orthopantomograms in detection of tooth root protrusion in the maxillary sinus: correlation result with cone beam computed tomography. *J. Oral Maxillofac. Res.* 1(1): e6.
- Neugebauer, J., Shirani, R., Mischkowski, R.A., Ritter, L., Scheer, M., Keeve, E. & Zöller, J.E. 2008. Comparison of cone-beam volumetric imaging and combined plain radiographs for localization of the mandibular canal before removal of impacted lower third molars. *Oral Surg. Oral Med. Oral Pathol. Oral Radiol. Endod.* 105(5): 633-642.
- Neves, F.S., Souza, T.C., Almeida, S.M., Haiter-Neto, F., Freitas, D.Q. & Bóscolo, F.N. 2012. Correlation of panoramic radiography and cone beam CT findings in the assessment of the relationship between impacted mandibular third molars and the mandibular canal. *Dentomaxillofacial Radiology* 41(7): 553-557.
- Peker, I., Sarikir, C., Alkurt, M.T. & Zor, Z.F. 2014. Panoramic radiography and cone-beam computed tomography findings in preoperative examination of impacted mandibular third molars. *BMC Oral Health* 14: 71.
- Sawamura, T., Minowa, K. & Nakamura, M. 2003. Impacted teeth in the maxilla: Usefulness of 3D Dental-CT for preoperative evaluation. *Eur. J. Radiol.* 47(3): 221-226.
- Scarfe, W.C. & Farman, A.G. 2008. What is cone-beam CT and how does it work? *Dent. Clin. North Am.* 52: 707-730.
- SEDENTEXCT project. 2011. *Radiation Protection: Cone Beam CT for Dental and Maxillofacial Radiology. Evidence Based Guidelines* 2011. [http://www.sedentextct.eu/files/guidelines\\_final.pdf](http://www.sedentextct.eu/files/guidelines_final.pdf). Accessed on 20 March 2012.
- Snyder, R.L. 2007. *Cone Beam Computed Tomographic Simulation of Panoramic Radiology: Third Molar Assessment and Mandibular Canal*. <http://search.proquest.com/docview/304848862/previewPDF?accountid=41453>. Accessed on 15 August 2013.
- Susarla, S.M. & Dodson, T.B. 2007. Preoperative computed tomography imaging in the management of impacted mandibular third molars. *J. Oral Maxillofac. Surg.* 65(1): 83-88.
- Tantanapornkul, W., Okouchi, K., Fujiwara, Y., Yamashiro, M., Maruoka, Y., Ohbayashi, N. & Kurabayashi, T. 2007. A comparative study of cone-beam computed tomography and conventional panoramic radiography in assessing the topographic relationship between the mandibular canal and impacted third molars. *Oral Surg. Oral Med. Oral Pathol. Oral Radiol. Endod.* 103(2): 253-259.
- Azizah Ahmad Fauzi  
Department of Oral Biology (Clinical), Faculty of Dentistry  
Universiti Kebangsaan Malaysia  
Jalan Raja Muda Abd Aziz  
50300 Kuala Lumpur, Federal Territory  
Malaysia
- Mohamed Ebrahim Parker & EJ Norval  
Department of Oral & Maxillofacial Diagnostic Imaging  
University of the Western Cape  
Robert Sobukwe Road  
Bellville, 7535  
Republic of South Africa
- Phrabhakaran Nambiar  
Department of Diagnostic & Integrated Dental Practice.  
University of Malaya  
50603 Kuala Lumpur, Federal Territory  
Malaysia
- \*Corresponding author; email: azizah\_fauzi@yahoo.com
- Received: 26 March 2015  
Accepted: 28 April 2016